

Recommendations for the management of hemophagocytic lymphohistiocytosis in adults

Paul La Rosée,¹ AnnaCarin Horne,² Melissa Hines,³ Tatiana von Bahr Greenwood,² Rafal Machowicz,⁴ Nancy Berliner,⁵ Sebastian Birndt,⁶ Juana Gil-Herrera,⁷ Michael Girschikofsky,⁸ Michael B. Jordan,^{9,10} Jan A. M. van Laar,¹¹ Gunnar Lachmann,¹² Kim E. Nichols,¹³ Athimalaipet V. Ramanam,¹⁴ Yini Wang,¹⁵ Zhao Wang,¹⁵ Gritta Janka,¹⁶ and Jan-Inge Henter²

¹Klinik für Innere Medizin II, Schwarzwald-Baar-Klinikum, Villingen-Schwenningen, Germany; ²Childhood Cancer Research Unit, Department of Women's and Children's Health, Karolinska Institute, and Theme of Children's and Women's Health, Karolinska University Hospital, Stockholm, Sweden; ³Division of Critical Care Medicine, St. Jude Children's Research Hospital, Memphis, TN; ⁴Department of Hematology, Oncology, and Internal Diseases, Medical University of Warsaw, Warsaw, Poland; ⁵Department of Medicine, Brigham and Women's Hospital, Harvard Medical School, Boston, MA; ⁶Klinik für Innere Medizin II, Universitätsklinikum Jena, Jena, Germany; ⁷Division of Immunology, Hospital General Universitario and Health Research Institute Gregorio Marañón, Madrid, Spain; ⁸Internal Medicine I, Ordensklinikum Linz Elisabethinen, Linz, Austria; ⁹Division of Immunobiology and Bone Marrow Transplantation and ¹⁰Division of Immune Deficiency, Cincinnati Children's Hospital Medical Center, University of Cincinnati, Cincinnati, OH; ¹¹Section of Clinical Immunology, Department of Internal Medicine and Immunology, Erasmus University Medical Center, Rotterdam, The Netherlands; ¹²Department of Anesthesiology and Operative Intensive Care Medicine (Charité Campus Mitte, Charité Virchow-Klinikum), Charité-Universitätsmedizin Berlin, Berlin, Germany; ¹³Division of Cancer Predisposition, St. Jude Children's Research Hospital, Memphis, TN; ¹⁴University Hospitals Bristol National Health Service Foundation Trust and Bristol Medical School, University of Bristol, Bristol, United Kingdom; ¹⁵Department of Hematology, Beijing Friendship Hospital, Capital Medical University, Beijing, China; and ¹⁶Clinic of Pediatric Hematology and Oncology, University Medical Center Eppendorf, Hamburg, Germany

Hemophagocytic lymphohistiocytosis (HLH) is a severe hyperinflammatory syndrome induced by aberrantly activated macrophages and cytotoxic T cells. The primary (genetic) form, caused by mutations affecting lymphocyte cytotoxicity and immune regulation, is most common in children, whereas the secondary (acquired) form is most frequent in adults. Secondary HLH is commonly triggered by infections or malignancies but may also be induced by autoinflammatory/autoimmune disorders, in which case it is called macrophage activation syndrome (MAS; or MAS-HLH). Most information on the diagnosis and treatment of HLH comes from the pediatric literature. Although helpful in some adult cases, this raises several challenges. For example, the HLH-2004 diagnostic criteria developed for children are commonly applied but are not validated for adults. Another challenge

in HLH diagnosis is that patients may present with a phenotype indistinguishable from sepsis or multiple organ dysfunction syndrome. Treatment algorithms targeting hyperinflammation are frequently based on pediatric protocols, such as HLH-94 and HLH-2004, which may result in overtreatment and unnecessary toxicity in adults. Therefore, dose reductions, individualized tailoring of treatment duration, and an age-dependent modified diagnostic approach are to be considered. Here, we present expert opinions derived from an interdisciplinary working group on adult HLH, sponsored by the Histiocyte Society, to facilitate knowledge transfer between physicians caring for pediatric and adult patients with HLH, with the aim to improve the outcome for adult patients affected by HLH. (*Blood*. 2019;133(23):2465-2477)

Introduction

Hemophagocytic lymphohistiocytosis (HLH) has become more widely recognized in adults, with all ages affected. Patients often suffer from recurrent fever, cytopenia, liver dysfunction, and a sepsis-like syndrome that may rapidly progress to terminal multiple organ failure. Subspecialists in hematology/oncology, infectious diseases, rheumatology/clinical immunology, gastroenterology/hepatology, neurology, emergency medicine, intensive care, and general medicine are challenged by this rare multifaceted syndrome. Physicians should be aware of HLH, because early recognition may prevent irreversible organ damage and subsequent death.^{1,2}

Although familial (primary) HLH (FHL), a major HLH subtype in children, can also occur in adolescents and young adults,

secondary (acquired) HLH (sHLH) is by far the most common in these age groups. The treatment protocols HLH-94 and HLH-2004 have been established as scientific cornerstones for diagnosis, classification, and treatment of HLH in patients younger than 18 years.³⁻⁵

Our current views on HLH are driven by lessons learned in pediatrics, and pediatricians still often consult on adults with HLH. However, HLH triggers, organ reserve, fitness, and clinical presentation differ between the pediatric and adult age groups. Transferring pediatric precepts regarding pathogenesis, diagnostics, and treatment of HLH to adult patients may confer risks. Therefore, the HLH Steering Committee of the Histiocyte Society developed these recommendations for diagnosis and treatment of HLH in adults, as a complement to previously published recommendations on etoposide-based therapy in HLH.⁶

Methods

Procedure

The recommendations are based on expert opinion supported by best available evidence from studies supporting the individual statements. They were initially proposed and discussed by e-mail and then selected and structured in a telephone conference. After further refinement by e-mail, each statement was discussed, revised, and voted on in face-to-face meeting, followed by final refinement by e-mail. The consensus strength for the statements was classified as follows:

- Strong consensus: >95% of participants agree
- Consensus: 75% to 95% of participants agree
- Majority agreement: 50% to 75% of participants agree
- No consensus: ≤50% of participants agree

Constitution of Recommendation Committee

The authors represent the current members of the Working Group "HLH in Adults" of the Histiocyte Society (www.histiocytesociety.org). The current head of the Working Group (P.L.R.) served as coordinator. The following medical subspecialties were represented: adult hematology/oncology and internal medicine (P.L.R., R.M., N.B., S.B., M.G., Y.W., Z.W.), pediatric hematology/oncology (T.v.B.G., M.B.J., A.K., K.E.N., G.J., J.-I.H.), rheumatology/clinical immunology (adult: J.A.M.v.L., A.V.R.; pediatric: A.H.), intensive care (adult: G.L.; pediatric: M.H.), and genetics/clinical immunology (J.G.-H.).

Pathogenesis and epidemiology of HLH

Statement 1: Primary and secondary HLH, including MAS-HLH, are hyperferritinemic hyperinflammatory syndromes with a common terminal pathway but with different pathogenetic roots (strong consensus).

HLH is an aberrant hyperinflammatory hyperferritinemic immune response syndrome that is driven by T cells and associated with a potentially fatal cytokine storm.^{7,8} The term "macrophage activation syndrome" (MAS; or MAS-HLH) refers to a subset of patients with HLH arising on a background of systemic autoinflammation/autoimmunity and should be restricted to patients with Still's disease, lupus, vasculitis, and other related autoimmune systemic diseases, because its treatment may differ from that recommended for other forms of sHLH^{9,10} (see Statement 14).

The current view of sHLH pathogenesis is an inability of the immune system to adequately restrict stimulatory effects of various triggers.^{7,10,11} Inherited variations in HLH-associated genes, which are well characterized in pediatric HLH, may play a role in adult-onset HLH, but acquired immune dysfunction in response to infections, malignancies, and autoinflammatory/autoimmune disorders seems to be the leading cause in adults (Table 1).^{10,12,13}

Statement 2: HLH triggers, including occult malignancies, require a meticulous search for the underlying disease that should be continued, despite ongoing HLH treatment (strong consensus).

Table 1. Causes of primary and secondary HLH

<p>Primary HLH (Mendelian inherited conditions leading to HLH) (Table 4)</p> <p>Defects in the cytolytic function of cytotoxic T cells and/or NK cells^{13,46,51}</p> <p>Defects in inflammasome regulation^{122,123}</p>
<p>Secondary HLH (apparently non-Mendelian HLH)¹⁰</p> <p>Infections (mainly viruses, such as EBV, HIV, and CMV, but also bacteria, parasites, and fungi)¹⁴</p> <p>Malignancies (mainly malignant lymphoma)¹⁵</p> <p>Macrophage activation syndrome in autoinflammatory or autoimmune disorders¹¹</p> <p>Other causes (organ or stem cell transplantation; metabolic, traumatic, iatrogenic [immunosuppression, vaccination, surgery, hemodialysis] causes; and, rarely, pregnancy)^{10,14}</p>

CMV, cytomegalovirus; EBV, Epstein-Barr virus.

Infections are the most prevalent triggers of HLH.^{10,14} In adults, particularly with increasing age, malignancies, primarily lymphomas, are another major cause (Table 1).^{10,15-17} A variety of malignancies are associated with HLH in adults, including T-cell or natural killer (NK) cell lymphomas (35%), B-cell lymphomas (32%), leukemias (6%), Hodgkin lymphoma (6%), other hematologic neoplasms (14%), solid tumors (3%), and other nonspecified neoplasms (3%).^{10,15}

The epidemiology of HLH varies substantially as a result of population heterogeneity and variable underlying triggers.¹⁷⁻²² A large literature review on adult HLH reported a mean age at HLH onset of 49 years (63% males).¹⁰ The reported incidence of malignancy-associated HLH varies from 1% in patients with hematological malignancies (0.36/100 000 individuals per year)¹⁷ to a cumulative incidence rate of 2.8% in patients with malignant lymphoma²³ and 9% of patients with acute myeloid leukemia (AML) after intensive induction therapy.²²

Diagnosis of HLH in adults

Statement 3: The diagnosis of HLH in adults should be based on the HLH-2004 diagnostic criteria in conjunction with clinical judgment and the patient's history (strong consensus).

The HLH-2004 diagnostic criteria

In 1991, the Histiocyte Society proposed a standardized set of 5 diagnostic criteria for HLH used for the prospective HLH-94 clinical trial.²⁴ These criteria were revised for HLH-2004: individuals needed to meet ≥5 of 8 diagnostic criteria (Table 2).^{4,5} On occasion, HLH may be strongly considered, and HLH-directed therapy may be initiated, even though 5 criteria are not fulfilled (see Statements 4, 6, 7, 10, and 13).⁶

Hyperferritinemia should always prompt inclusion of HLH in the differential diagnosis.²⁵ Ferritin values characteristic of HLH in adults are often >7000 to 10 000 μg/L and, rarely, may be >100 000 μg/L.²⁶ Ferritin levels >10 000 μg/L are >90% sensitive and specific for HLH in children, although other criteria need to be met to make the diagnosis. Although a ferritin level in this range should also raise a strong suspicion of HLH in adults, hyperferritinemia is less specific. Integration of a number of clinical features is required to confirm the diagnosis HLH in

Table 2. HLH-2004 diagnostic criteria

The diagnosis of HLH can be established if Criterion 1 or 2 is fulfilled.
1. A molecular diagnosis consistent with HLH
2. Diagnostic criteria for HLH fulfilled (5 of the 8 criteria below)
Fever
Splenomegaly
Cytopenias (affecting ≥ 2 of 3 lineages in the peripheral blood)
Hemoglobin < 90 g/L (hemoglobin < 100 g/L in infants < 4 wk)
Platelets $< 100 \times 10^9/L$
Neutrophils $< 1.0 \times 10^9/L$
Hypertriglyceridemia and/or hypofibrinogenemia
Fasting triglycerides ≥ 3.0 mmol/L (ie, ≥ 265 mg/dL)
Fibrinogen ≤ 1.5 g/L
Hemophagocytosis in bone marrow or spleen or lymph nodes. No evidence of malignancy.
Low or no NK cell activity (according to local laboratory reference)
Ferritin ≥ 500 $\mu\text{g/L}$
sCD25 (ie, soluble IL-2 receptor) ≥ 2400 U/mL

If hemophagocytic activity is not proven at the time of presentation, further search for hemophagocytic activity is encouraged. If the bone marrow specimen is not conclusive, material may be obtained from other organs. Serial marrow aspirates over time may also be helpful. The following findings may provide strong supportive evidence for the diagnosis: spinal fluid pleocytosis (mononuclear cells) and/or elevated spinal fluid protein and histological picture in the liver resembling chronic persistent hepatitis (biopsy). Other abnormal clinical and laboratory findings consistent with the diagnosis are cerebromeningeal symptoms, lymph node enlargement, jaundice, edema, skin rash, hepatic enzyme abnormalities, hypoproteinemia, hyponatremia, and elevated very low-density lipoprotein (VLDL \uparrow)/low high-density lipoprotein (HDL).

adults.^{27,28} Soluble interleukin-2 (IL-2) receptor (also soluble CD25 [sCD25]), 1 of the diagnostic criteria in HLH-2004, has recently been reported as a good to excellent low-cost diagnostic test for adult HLH, with an area under the curve of 0.90 (95% confidence interval, 0.83-0.97) compared with an area under the curve of 0.78 (95% confidence interval, 0.67-0.88) for ferritin.^{29,30} The HLH-2004 criteria, developed for children, are not validated formally for adults and remain based on expert opinion. Various case series have used modified HLH-2004 criteria.^{19,21,31-41}

Other diagnostic tools

Other features supporting an HLH diagnosis that are not part of the HLH-2004 criteria include hyperbilirubinemia, hepatomegaly, transaminitis (present in the vast majority of patients with HLH), and elevated lactate dehydrogenase and D-dimer levels, with the latter usually elevated even when international normalized ratio, partial thromboplastin time, and fibrinogen are normal. These findings may help to discriminate HLH from septic shock and conditions such as autoimmune hemolytic anemia, and they are also useful in assessing response to therapy.

The HLH-probability calculator (HScore), with graded clinical and laboratory parameters, is a Web-based online calculator (<http://saintantoine.aphp.fr/score/>) developed retrospectively in adult patients that may be a helpful diagnostic tool (Table 3).⁴² The pattern of inflammatory cytokines (elevated levels of interferon- γ [IFN- γ] and IL-10, with only modestly elevated IL-6 levels) has high diagnostic accuracy for sHLH and may be a useful approach to differentiate HLH from infection and to monitor patients; however, the utility of this pattern of changes needs to be verified in children and adults outside of China.⁴³⁻⁴⁵ For diagnosis using functional assessment of cytotoxicity and genetics, see Statement 4.

Clinical phenotypes

Many adult patients with HLH present with the triad of fever, bicytopenia with potential bleeding diathesis, and splenomegaly. Wasting and fatigue may occur. Edema, purpura, dyspnea, diarrhea, diffuse bleeding, icterus, and an overall sepsis-like appearance are extremes of severe HLH with onset of organ failure. Mild initial signs, including recurrent fevers, lymphadenopathy, organomegaly, rash, and arthralgias, may progress with an unexpected rapidity and severity. These signs and symptoms, despite adequate antimicrobial therapy and/or without detectable infectious focus, along with a dramatic clinical progression serve as red flags for possible HLH. No single clinical or laboratory parameter has sensitivity and specificity to allow an unambiguous HLH diagnosis. Close clinical observation with repeated physical examinations and laboratory assessments are mandatory for diagnosis.

Statement 4: Diagnostic tests for genetic HLH include functional assessment of lymphocyte cytotoxicity and guided genetic testing. They are useful for detecting potential genetic predisposition to HLH in select patients, but pending results must not delay the clinical decision to treat HLH (consensus).

Functional and genetic testing are not generally recommended in adult patients with HLH because abnormalities are rarely detected. Genetic defects leading to FHL, with impairment of lymphocyte cytotoxicity, and genetic alterations in related disorders are presented in Table 4.^{13,46-50} Although most patients with underlying genetic defects show the features summarized in Table 4, cellular expression of perforin, SLAM-associated

Table 3. Parameters and points in the HScore

Parameter	No. of points (criteria for scoring)
Known underlying immunosuppression*	0 (no) or 18 (yes)
Temperature (°C)	0 (< 38.4), 33 (38.4–39.4), or 49 (> 39.4)
Organomegaly	0 (no), 23 (hepatomegaly or splenomegaly), or 38 (hepatomegaly and splenomegaly)
No. of cytopenias†	0 (1 lineage), 24 (2 lineages), or 34 (3 lineages)
Ferritin ($\mu\text{g/L}$)	0 (< 2000), 35 (2000-6000), or 50 (> 6000)
Triglyceride (mmol/L)	0 (< 1.5), 44 (1.5-4), or 64 (> 4)
Fibrinogen (g/L)	0 (> 2.5) or 30 (≤ 2.5)
Aspartate aminotransferase (U/L)	0 (< 30) or 19 (≥ 30)
Hemophagocytosis on bone marrow aspirate	0 (no) or 35 (yes)

*HIV positive or receiving long-term immunosuppressive therapy (ie, glucocorticoids, cyclosporine A, azathioprine).
 †Defined as a hemoglobin level of 9.2 g/L and/or a leukocyte count $\leq 5 \times 10^9/L$ and/or a platelet count $\leq 110 \times 10^9/L$.

Table 4. Genetic alterations in primary HLH and related disorders of immunoregulation

Defective immune function	Gene* (locus)	Syndrome	Clinical features	Laboratory findings
Cytotoxic granule content	<i>PRF1</i> (10q21-22)	FHL2		Decreased/absent perforin expression (FC)
Cytotoxic exocytosis pathway	<i>UNC13D</i> (17q2)	FHL3		Low CD107a expression (degranulation assay, FC)
	<i>STX11</i> (6q24)	FHL4		Low CD107a expression (degranulation assay, FC)
	<i>STXBP2</i> (19p13)	FHL5	Colitis, sensorineural hearing loss	Low CD107a expression (degranulation assay, FC)
	<i>RAB27A</i> (15q21)	Griscelli type 2	Hypopigmentation	Abnormal granule pattern in CBC and hair shafts, low CD107a expression
	<i>LYST</i> (1q42-43)	Chediak-Higashi	Hypopigmentation	Abnormal granule pattern in CBC and hair shafts, low CD107a expression
Cytotoxic T-cell signaling	<i>SH2D1A</i> (Xq24-25)	XLP1 Duncan disease	EBV lymphoproliferation	Decreased/absent SAP expression, reduced NK T cells (FC), hypogammaglobulinemia
Inflammasome regulation, excess apoptosis, NOD signal	<i>BIRC4</i> (Xq25)		Refractory colitis, EBV lymphoproliferation	Decreased/absent BIRC4 protein expression, reduced NK T cells
Inflammasome constitutive activation	<i>NLRC4</i> (2p22.3)	XLP2	Recurrent autoinflammation, enterocolitis	High circulating IL-18 levels

CBC, complete blood count; EBV, Epstein-Barr virus; FC, flow cytometry; NOD, nucleotide-binding oligomerization domain-like receptor; SAP, SLAM-associated protein; XLP, X-linked lymphoproliferative syndrome.

*Genes associated with other rare immune deficiencies that may cause the HLH syndrome include *ITK* (5q33), *CD27* (12p13.31), *RAG1&2* (11p12), *IL2RG* (Xq13.1), *IL7RA* (5p13.2), *CD3E* (11q23.3), *BTK* (Xq22.1), *FAS* (10q23.31), *WAS* (Xp11.23), *ATM* (11q22.3), *NEMO* (Xq28), *STAT1* (2q32.2), *DKC1* (Xq28), *MEFV* (16p13.3), and *TNFRSF1A* (12p13.31), as well as *CYBB* (Xp21.1-p11.4), *CYBA* (16q24.2), and *NCF1* (7q11.23) which encode the phagocyte reduced NAD phosphate oxidase complex affected in chronic granulomatous disease.^{13,46,124}

protein, X-linked inhibitor of apoptosis protein proteins, or CD107a (a glycoprotein necessary for degranulation [exocytosis] of perforin-containing granules from cytotoxic lymphocytes) may be normal or nearly normal in rare cases.⁵⁰ To determine whether a patient has an inherited form of HLH, genetic analyses (ie, next-generation sequencing, gene panels, whole-exome sequencing), along with functional testing (ie, NK cell cytotoxicity and CD107a upregulation), will be needed.^{10,15-17,46,51} This is particularly true for patients with a family history of consanguinity and/or HLH, partial albinism, or recurrent disease and for young male adults with Epstein-Barr virus (EBV) infection or lymphoproliferation. Testing should also be considered for HLH patients with unknown trigger. Importantly, pending results must not delay the clinical decision to treat HLH.

Although primary HLH is rare in adults, mutations in HLH-associated genes can be detected in adult patients with HLH (Table 5)⁵¹; in the United States, a rate of 7% (12/175) is reported.⁵² However, the predominant locus, the A91V mutation in *PRF1*, is considered a hypomorphic mutation that is present in up to 10% of healthy whites.⁵³ Although these hypomorphic alleles may constitute a risk factor for HLH, the vast majority of individuals carrying these mutations have no clinical symptoms.

Statement 5: Lymphoma as a hidden trigger of HLH may be difficult to detect. Use of positron emission tomography-guided imaging, repetitive tissue sampling, and consultation with

a lymphoma reference pathologist, are recommended (strong consensus).

About 40% to 70% of HLH cases in adults are malignancy associated, triggered by the malignancy itself at presentation or seen after initiation of chemotherapy; the latter may even occur in patients in remission and is thought to be due to immunosuppression and/or infection.¹⁵ Therefore, patients need a thorough cancer workup, with special consideration of Hodgkin lymphoma and non-Hodgkin lymphoma (NHL). Atypical presentation and certain lymphoma subtypes (ie, Hodgkin; diffuse large B-cell lymphoma, intranasal subtype; NK/T-cell lymphoma; angioimmunoblastic T-cell lymphoma; anaplastic large cell lymphoma; panniculitis-like T-cell NHL; intravascular B-cell lymphoma; and peripheral T-cell lymphoma) are more strongly associated with HLH.^{54,55} Computed tomography scan enhanced by positron emission tomography, followed by biopsy of suspicious lesions, is advised to reveal occult disease.⁵⁶ An elevated sCD25/ferritin ratio has been reported in lymphoma-associated HLH.⁵⁷

Tumor-infiltrating reactive lymphocytes can mask an underlying lymphoma. Thus, a close interaction among clinicians, pathologists, and immunologists is required to determine the correct diagnosis. In individuals with HLH of unknown cause and splenomegaly, splenectomy may be considered to detect lymphomas hiding in the spleen or perisplenic tissue. This is justified

Table 5. Overview of HLH-associated sequence variants found in adults in selected registries

Reference	Mutation frequency	PRF1 bi/mo	STXBP2 bi/mo	SH2D1A hemi/mo	UNC13D bi/mo	STX11 bi/mo	Age (range), y
Zhang et al ⁵²	14%	7/11*	1/1*	0/0	2/5*	0/0	≥18, n = 25
Sieni et al ¹²⁵	n/a	6/0	1/0	2 (m)/0	2/0	0/0	23 (18-43), n = 11
Wang et al ⁴¹	7%	6/3*	0/0	1 (m)*/1 (f)	0/1	0/7	20 (13-56), n = 18
Cetica et al ^{51†,‡}	25%	—	—	—	—	—	≥18, n = 44
Chen et al ^{126†}	32%	1/2*	0/1	0	1*/2	0	≥18, n = 22

bi, biallelic mutation; f, female; hemi, hemizygous mutation; m, male; mo, monoallelic mutation.

*Some are double-heterozygous patients, with mutations in 2 different genes.

†The study included all age groups.

‡Only biallelic variations reported. Specific mutant site not reported for patients ≥18 years.

in clinical circumstances that strongly support lymphoma (history of B symptoms, weight loss, elevated sCD25/ferritin ratio).⁵⁸

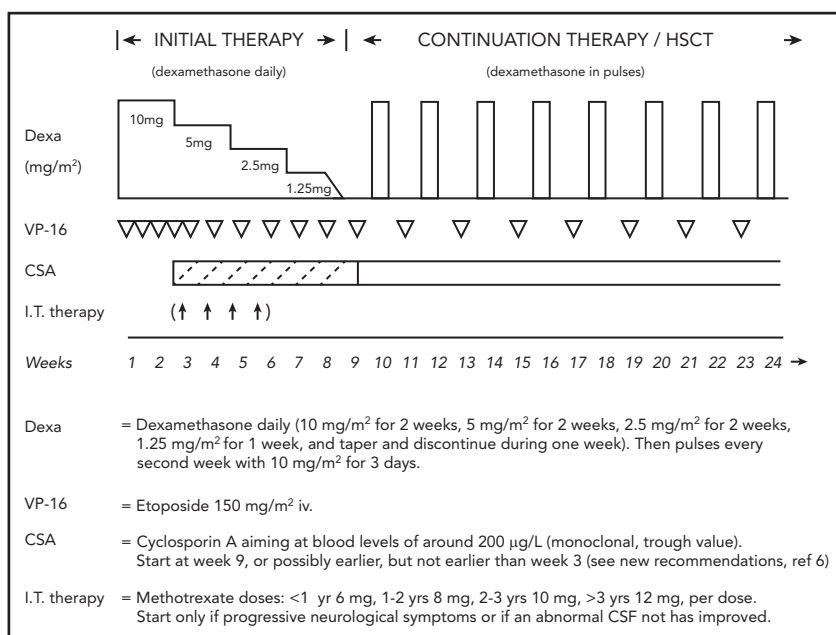
Treatment of adult patients with HLH

Statement 6: HLH-94 treatment components, including etoposide, are highly effective in treating hyperinflammation in adults with HLH (Figure 1) (strong consensus).

The heterogeneity of adult HLH prohibits a “1-size-fits-all protocol” (Figure 2). The HLH-94 protocol drastically improved the nearly uniformly fatal outcome in pediatric HLH to a long-term survival >50%.³ The HLH-94 protocol consists of corticosteroids, typically dexamethasone, cyclosporine A (CSA), intrathecal therapy, and etoposide, to delete activated T cells and suppress inflammatory cytokine production (Figure 1).⁶ Etoposide, a chemotherapeutic agent, has high specificity against T-cell proliferation and cytokine secretion in mice.⁵⁹ However, adult, and especially, elderly patients may have chronic comorbidities,

making them more vulnerable to end organ damage caused by cytokine storm in HLH and HLH-94 chemotherapy. A reduced etoposide frequency, from twice weekly to once a week, with or without a reduction in dose from 150 mg/m² to 50-100 mg/m², should be considered. In the HLH-2004 study, CSA was administered upfront instead of after 8 weeks, as in HLH-94, and pre-stem cell transplantation (SCT) mortality was reduced from 27% to 19% (*P* = .064 adjusted for age and sex). Because this improvement was not significant and because CSA is associated with side effects, as well as contraindications, particularly early in the disease course, HLH-94 remains the recommended standard of care.⁵ In HLH-94, intrathecal therapy is only suggested in case of progressive neurological symptoms after 2 weeks of therapy or if an abnormal cerebrospinal fluid has not improved by then (Figure 1).

The risk of children developing treatment-related AML in the HLH-2004 and HLH-94 studies was 0.3% (1/368) to 0.4% (1/249) at a median follow-up of 5.2 and 6.2 years, respectively,^{3,5,6} and



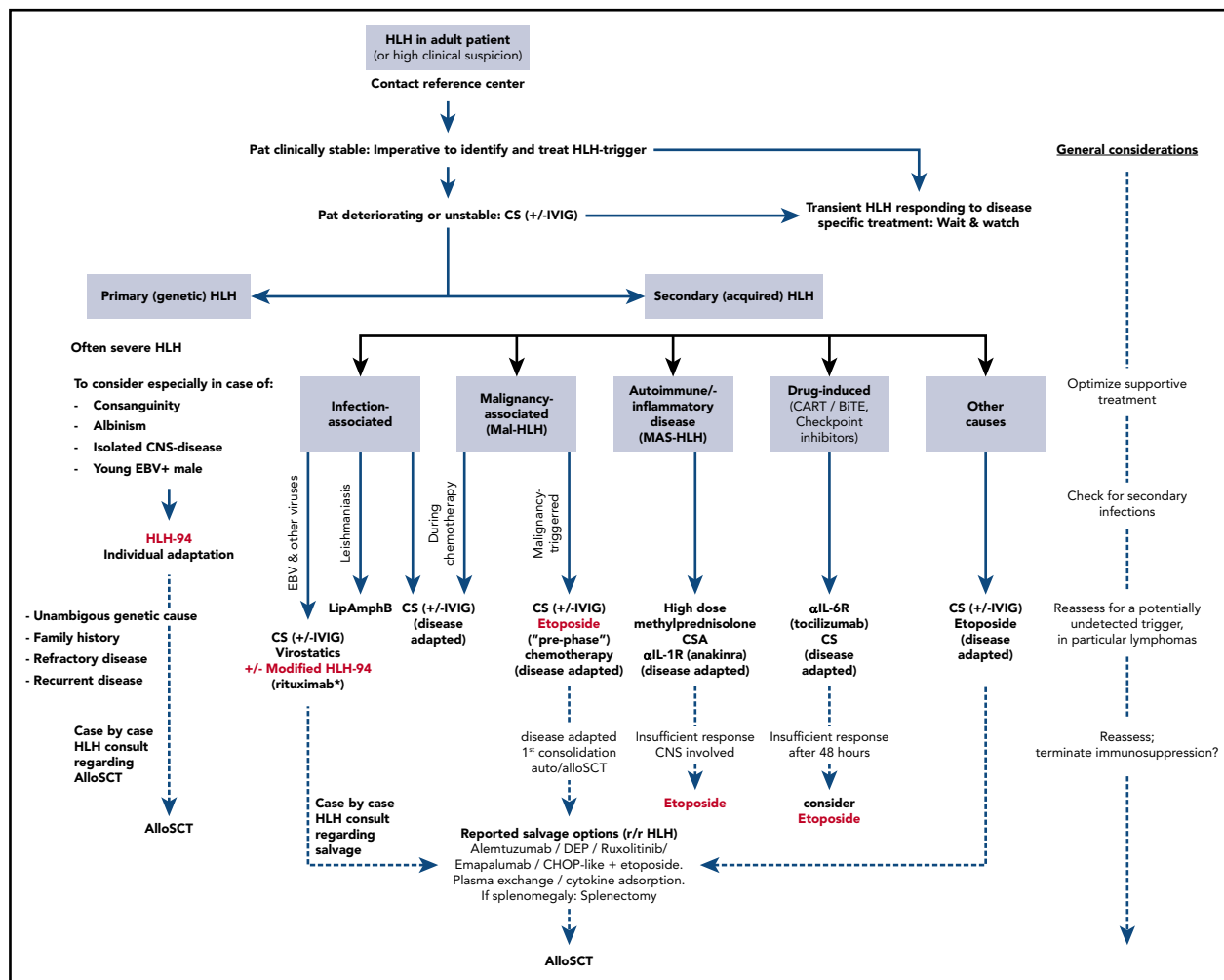


Figure 2. Treatment algorithm for adult patients with HLH, including MAS-HLH. The HLH-94 pediatric treatment protocol is the consensus mainstay treatment of newborns, toddlers, and children up to 18 years of age, where genetic causes of HLH are enriched. Individual adaptation regarding the length and dosing of the HLH-94 treatment plan in adults is warranted. Allogeneic hematopoietic stem cell transplant (alloSCT) can cure primary HLH and may be applied in patients with high-risk hematologic malignancy as consolidation treatment or in relapsed HLH after successful salvage treatment. Treatment in adults cannot be standardized and needs tailoring according to the underlying condition and HLH-initiating trigger (infection, malignancy, autoimmune/autoinflammatory, drug induced, other causes). In relapsed/refractory (r/r) HLH, treatment intensification with chemotherapy, use of the anti-CD52 antibody alemtuzumab, cytokine adsorption using filter columns or plasma exchange, off-label treatment with the JAK2 inhibitor ruxolitinib, or the anti-IFN- γ antibody emapalumab have shown reasonable efficacy. BITE, bispecific T-cell engager; CART, chimeric antigen receptor T cells; CHOP, cyclophosphamide, doxorubicin, vincristine, prednisone; CS, corticosteroids; DEP, doxorubicin, etoposide, methylprednisolone; IVIG, polyvalent immunoglobulins; Pat, patient. *Off-label in EBV-HLH.

1.2% (1/81) in patients with EBV-associated HLH (EBV-HLH) treated with a median cumulative etoposide dose of 1500 mg/m² body surface area, with a median follow-up of 44 months.⁶⁰ The need to stay below a cumulative dose of 2-3 g/m² should be kept in mind, particularly in HLH patients without malignancy.⁶⁰

Allogeneic SCT

Adults with primary HLH may need allogeneic hematopoietic SCT (alloSCT), which has dramatically improved outcomes in children.⁶¹ Transplant-related mortality in children using reduced-intensity conditioning (RIC) has been reported to compare favorably to myeloablative conditioning (MAC).⁶² A retrospective European Society of Blood and Marrow Transplantation study did not show superiority of RIC over MAC in adults.⁶³ Decisions regarding transplantation should be made on clinical grounds and in consultation with experts in HLH and alloSCT. Inactive HLH before transplantation is strongly associated with better survival.⁶⁴ Patients with primary HLH and nonmalignant sHLH may be candidates for

RIC, as well as MAC. The pretransplant conditioning regimen in malignancy-associated HLH (Mal-HLH) may be guided by disease-specific protocols, as provided by local standards, which includes MAC to optimally control the underlying disease. In patients in whom HLH-causing mutations are detected, HLA typing of close relatives should also integrate screening for the same gene mutations, to avoid a stem cell source with the same pathogenic biallelic mutation(s).

Statement 7: The variable severity of HLH, including MAS-HLH, demands graded intensity and length of treatment. Treatment should be tailored to control hyperinflammation and to treat identified disease triggers (strong consensus).

An HLH diagnosis may be suspected, but not confirmed, by the presence of 5 of 8 HLH-2004 criteria. Resolution of HLH without HLH-specific treatment has been observed, particularly in infection-associated HLH.⁶⁵ In moderately active HLH, the

decision to start HLH-directed treatment depends on clinical judgment and assessment of organ function. Pulsed corticosteroids and elements of HLH-94 (dexamethasone 10 mg/m² with/without a modified dose of etoposide) may be used. A clear indication for immediate administration of etoposide is severe HLH presenting with imminent organ failure.^{33,66} Individualized modified HLH-94-like treatment has been suggested in sHLH.⁶⁷ Because etoposide is primarily cleared by the kidneys, dose reduction is recommended if renal function is impaired based on age-specific norms (for dose recommendations see Ehl et al⁶), whereas no dose reduction of etoposide is recommended for isolated hyperbilirubinemia and/or elevated transaminases.

Addition of IV immunoglobulin (IVIg) (up to 1.6 g/kg in split doses over 2-3 days) may be considered,⁹ because IVIg has anti-inflammatory potential by inhibiting complement activation, blocking antibody Fc fragments and macrophage Fc receptors, and neutralizing cytokines.^{68,69} However, the use of IVIg has been questioned, at least in adult-onset Still's disease.⁷⁰ Anakinra may reduce mortality in sepsis patients with MAS features.⁷¹

Many patients with sHLH require <8 weeks of etoposide. Although patients may be continued on the full course (8 weeks) of etoposide in the absence of major toxicities, we recommend a weekly reevaluation of the need for continued etoposide therapy. Patients with residual disease after 8 weeks may benefit from maintenance therapy and, possibly, alloSCT. For those requiring alloSCT because of underlying genetic mutations, HLH-94 maintenance therapy is often recommended after the initial 8 weeks of therapy.⁶ CSA may be replaced by tacrolimus, but both need careful drug level monitoring and toxicity assessment.²⁷

Statement 8: Secondary infections are a major cause of fatality and may erroneously be diagnosed as HLH relapse (strong consensus).

Certain HLH triggers carry the inherent risk of acquired cellular immunodeficiency, such as Hodgkin lymphoma, T-cell lymphomas, or HIV. Additionally, HLH-directed treatment depletes leukocytes (T/B cells and granulocytes). For patients requiring such treatment, administration of broad antimicrobial prophylaxis against *Pneumocystis jirovecii* and fungi is recommended. Hospitalization in units with high efficiency particulate air-filtered air should be considered. We also suggest antiviral prophylaxis because of the severe T-cell depletion.

Mal-HLH

Statement 9: Mal-HLH comes in 2 forms: "malignancy-triggered HLH" as a presenting feature of the malignancy at diagnosis or at relapse and "HLH during chemotherapy," in most cases induced by infections. Differentiating these HLH subtypes is important, because the therapeutic approach differs markedly (strong consensus).

Mal-HLH has the worst prognosis of all of the HLH subgroups.³⁵ The risk of developing Mal-HLH increases with age.¹⁵ Lymphoma-associated HLH is the major cause of Mal-HLH, with region-specific subtype distribution (eg, increased rate of NK/T-cell and EBV-triggered lymphoma in Asia).

Malignancy-triggered HLH

Treatment of malignancy-triggered HLH needs to balance HLH-specific and tumor-specific treatment. Corticosteroids

are often used as first-line treatment to combat inflammation. In highly active HLH, or if severe organ damage is imminent, dose-adjusted etoposide (50-100 mg/m²) may be used prior to tumor-specific treatment.¹⁶ Etoposide can be added to CHOP or CHOP-like protocols (cyclophosphamide, doxorubicin, vincristine, etoposide, prednisone [CHOEP] or dose-adapted etoposide, prednisone, vincristine, cyclophosphamide, doxorubicin [DA-EPOCH]).⁹ Patients with aggressive lymphomas should be considered for evaluation of involvement of the central nervous system (CNS), with cerebral magnetic resonance imaging and lumbar puncture.⁷² Prophylactic or therapeutic age-adapted high-dose IV methotrexate may be considered individually to prevent CNS relapse (this treatment is not well tolerated by older patients). Patients in remission who are eligible for treatment intensification may be candidates for autologous SCT, using high-dose etoposide-containing chemotherapy as primary consolidation; this recommendation is based on the assumption that the dismal prognosis of lymphoma-associated HLH can be overcome by high-dose chemotherapy, which has been demonstrated in T-cell NHL.⁷³ A decision toward consolidation treatment by using alloSCT requires careful individual assessment (see Statement 12).⁷⁴

The co-occurrence of HLH and lymphoma, particularly EBV-driven lymphoma in younger patients, should trigger expert consultation and germline genetic testing, because evidence of HLH-associated mutations may support primary allogeneic, and not autologous, SCT.⁷⁵ Early HLA typing and donor search in Mal-HLH is advised in selected malignancies with potential indication for primary consolidation by alloSCT (eg, Burkitt lymphoma, acute leukemias, myelodysplastic syndromes).²⁷

HLH during chemotherapy

"HLH during chemotherapy" develops during or after treatment of a malignant disorder and is probably underrecognized. In neutropenic patients after induction chemotherapy for AML, as many as 9% may develop HLH with infections (fungal, bacterial, central-line associated) as the most frequent trigger.²² Diagnosis is obscured by preexisting neutropenia, liver function abnormalities that may be attributed to toxic drug effects, and increased ferritin that may be secondary to transfusion-related iron overload.

HLH has to be considered when cytopenia is unduly prolonged after chemotherapy, fever persists in spite of antibiotic treatment, and other HLH parameters are present. These patients benefit from anti-inflammatory treatment with corticosteroids (prednisolone 1-2 mg/kg or dexamethasone 5-10 mg/m²) and, possibly, IVIg 1.6 g/kg over 2 to 3 days. Etoposide should be used sparingly, because bone marrow recovery is central for immune reconstitution. Ongoing monitoring is required to detect recurrent malignant disease as a potential alternate HLH trigger. Where available, ferritin, sCD25, and bone marrow assessment (activated macrophages and/or hemophagocytosis) can help to distinguish those who are neutropenic as the result of chemotherapy from those who have underlying HLH.²²

Infection-associated HLH

Statement 10: Viral infections, in particular EBV, HIV, cytomegalovirus, or influenza, are common triggers of HLH (strong consensus).

EBV-HLH

In 1 review of 2197 adults with HLH, viral infections were the most frequent trigger, dominated by EBV.¹⁰ The prognosis for EBV-HLH has improved greatly when treated promptly using HLH-94 protocols, but the variable severity of EBV-HLH demands graded intensity and length of treatment.⁷⁶ Rapid clinical deterioration, in particular in treatment-naïve EBV-infected patients, mandates etoposide treatment without delay.³³ A more conservative approach with a short course of corticosteroids (with/without IVIG) is justified in patients with less severe disease or improving clinical manifestations. Monitoring of ferritin, sCD25, cell counts, and EBV DNA in affected patients aids in assessing treatment response.⁷⁷ EBV DNA levels $>10^3$ copies per milliliter have been reported to be relevant for the development of EBV-HLH.¹⁸

Because EBV replicates in B cells, the addition of rituximab (eg, 375 mg/m² once weekly, 2-4 times) to HLH-directed therapy may be effective in clearing the reservoir of virus in EBV-triggered HLH.⁷⁸ Monitoring of ferritin, sCD25, cell counts, and EBV DNA may guide the number of rituximab doses. However, in many cases, EBV-HLH is associated with infection of T cells and/or NK cells, irrespective of the patients' ethnic background or the clinical course,⁷⁹ so rituximab cannot replace the anti-T-cell therapy with corticosteroids with/without etoposide, as suggested above. In patients with continuously increasing or sustained high levels of EBV DNA, SCT should be considered, such as in chronic active EBV.^{80,81}

HIV-HLH

The prognosis of HLH in patients with HIV has improved in the era of highly active antiretroviral treatment.⁸² Lymphomas and opportunistic infections are the most important triggers to look for. A short transient treatment of overt inflammation by corticosteroids (with/without IVIG) is recommended. In a large series of patients with HLH secondary to HIV (HIV-HLH), etoposide was administered in about half.⁸² The wide spectrum of potential viral triggers mandates virus-specific treatment on a case-by-case basis.

Statement 11: HLH induced by intracellular infections, such as tuberculosis, leishmaniasis, or rickettsial disease, usually does not need HLH-94-like treatment but responds to specific antimicrobial treatment (strong consensus).

Patients infected by pathogens that target the monocyte-macrophage system may develop HLH, but immunosuppression as imparted by the HLH-94 protocol should be avoided, because they usually respond well to specific antimicrobial treatment. Leishmania is an endemic pathogen around the world, and treatment with (liposomal) amphotericin B cures leishmaniasis.⁸³ Rickettsial disease is treated by tetracyclines or chloramphenicol, whereas tuberculosis requires quadruple antibiotic treatment and adaptation according to resistance testing.⁸⁴

Salvage treatment of relapsed and refractory HLH

Statement 12: Salvage treatment of adults with refractory/relapsing HLH usually requires intensification using combined chemotherapy and consolidation with alloSCT (strong consensus).

Mortality in adult HLH ranges from 20% to 88%, primarily as the result of refractory HLH, secondary infections, and progression of the underlying triggering disease.¹⁹ In a prospective study, liposomal doxorubicin, etoposide, and high-dose methylprednisolone resulted in complete remission in 27% of patients and partial remission in 49% of patients within 4 weeks.⁸⁵

In infection-associated HLH, in particular EBV-HLH, reactivations are common if treatment intensity is only moderate or tapered too fast; such reactivations commonly respond to treatment intensification. For patients with EBV-HLH and persistent high EBV genome copy numbers or chronic active EBV and refractory/relapsing lymphoma, alloSCT is recommended.^{64,80,81,86} In primary HLH, reactivations and/or persistence of hyperinflammation are frequent until curative alloSCT is performed.^{5,6,61}

Data on the efficacy of salvage agents for HLH are limited. The anti-CD52 antibody alemtuzumab (median dose 1 mg/kg split over a median of 4 days) has been reported to be beneficial in refractory pediatric patients; a reduced dose or prolonged maintenance (as in chronic lymphocytic leukemia) has been used in young adults.^{87,88} Other salvage options include CHOP-like protocols plus etoposide and targeted inhibition of JAK signaling with ruxolitinib.^{89,90} Plasmapheresis or the use of cytokine adsorption columns may aid in rescuing critically ill patients from a deleterious cytokine storm.^{91,92} In November of 2018, the U.S. Food and Drug Administration approved emapalumab (anti-IFN- γ monoclonal antibody) as a second-line therapeutic agent for primary HLH in children and adults, after completion of an initial study that included 27 patients with relapsed/refractory disease. Emapalumab has the potential to be more readily tolerated than etoposide, although there has not yet been significant experience in the treatment of adults.⁹³

As a general rule, in patients with refractory HLH, treatment decisions need to be individualized according to the most likely triggering cause. In patients with Mal-HLH, treatment of the malignancy guides the salvage approach (intensification of chemotherapy). Contact with a HLH reference center is recommended.

HLH and MAS-HLH in the intensive care unit

Statement 13: In critically ill patients with persistent fever, cytopenias, and organomegaly, particularly in confirmed or presumed cases of sepsis, sepsis-like syndromes, and/or evolving multiorgan failure, suspicion for HLH should be raised and further HLH testing should be initiated (strong consensus).

Intensivists may be the first to diagnose HLH in patients with multiple organ dysfunction syndrome (MODS).^{94,95} Familiarity with HLH is important because of its nonspecific symptoms and laboratory findings, as well as that fact that the hyperinflammatory state of HLH can be observed in sepsis, MODS, and other cytokine storm syndromes. "Hyperinflammatory sepsis" (also described as "MAS-like") refers to patients who typically have less severe hyperinflammation and may not fulfill the diagnosis of HLH.^{71,96-98} Importantly, HLH, MODS, and sepsis can coexist, with sepsis serving as the possible HLH trigger.^{2,96,99} HLH should be considered in deteriorating critically ill patients with a disproportionate inflammatory response (eg, persistent

fever, unresponsiveness to vasopressors, need for extracorporeal life support), inexplicable cytopenias, and organ failure not responding to appropriate therapy, antimicrobial treatment, and aggressive supportive care.^{94,100} Screening for HLH should follow the HLH-2004 criteria, including bone marrow investigation (see Statement 3). Fever, 1 of the criteria, needs special consideration because it can be masked by frequent use of antipyretics, continuous renal replacement therapy, and extracorporeal life support.

Therapy should be individualized and include HLH or MAS-HLH-directed treatment (see Statements 6, 7, 10, 12, and 14), with consideration of standard supportive care and adjunctive critical care therapies.^{94,100-103} Reevaluation of the clinical condition should be frequent (at least every 12 hours) to determine whether initial or additional HLH-directed therapy is needed.

Clinical management of MAS-HLH

Statement 14: Treatment of MAS-HLH is different from that recommended for HLH as a result of partial pathogenetic diversity (strong consensus).

HLH in patients with underlying rheumatic conditions is historically called macrophage-activation syndrome (MAS; MAS-HLH). MAS-HLH, a form of sHLH that is increasingly recognized in adults, has been reported in association with almost all systemic rheumatic conditions.^{104,105} An overwhelming immune activation leads to a systemic cytokine storm, but the initiating factors might be different in MAS-HLH compared with other forms of HLH, although, like other forms of sHLH, MAS-HLH is commonly triggered by infections.^{8,10}

Currently, there are no accepted classification criteria for adult MAS-HLH. Several criteria have been developed for children, but these still need validation in adult patients (see Statement 3).^{42,106-109} Notably, symptoms of MAS-HLH may be different in patients treated with biologic agents.¹¹⁰

Early recognition and diagnosis of MAS-HLH are essential for efficacious management. A personalized and graded treatment approach is advised.¹⁰² Conventionally, corticosteroids are the first-line treatment. High-dose pulse methylprednisolone (1 g/d for 3-5 consecutive days) is 1 frequent initial approach.¹¹¹ CSA (2-7 mg/kg per day) can be added in patients with an insufficient immediate response, as well as IL-1-blocking therapy with anakinra¹¹²⁻¹¹⁴; a dose of 2 to 6 mg/kg up to 10 mg/kg per day subcutaneously in divided doses is suggested. Experience with anti-IL-6 blockade with tocilizumab is also increasing.¹¹⁴ Finally, in patients with severe active disease or CNS involvement, despite steroids, CSA, and/or anakinra, a reduced dose of etoposide (50-100 mg/m² once weekly) may be very effective¹⁰⁴; preferably, such treatment should be discussed with an expert but still not delayed.

HLH-like cytokine storm induced by novel immunotherapies

Statement 15: Novel immunotherapies may induce a cytokine storm resembling HLH that requires specific treatment (strong consensus).

With the advent of novel T-cell-engaging immunotherapies, reports of treatment-associated cytokine release syndrome have repeatedly emerged.^{115,116} These T-cell immunotherapies include engineered T cells, such as chimeric antigen receptor modified T (CART) cells targeting CD19, and blinatumomab, a bispecific T-cell engager antibody that connects CD3⁺ T cells to CD19⁺ target B cells.^{117,118} Both of these agents are approved for treatment of B-acute lymphoblastic leukemia. CART cells are also approved in relapsed/refractory B-cell NHL. CART cells and blinatumomab induce a cytokine response that strongly resembles other forms of HLH.

The anti-IL-6 antibody tocilizumab has been used with notable rapid resolution of cytokine release syndrome in patients after CART cell or blinatumomab treatment. More recently, there are increasing reports of treatment-induced HLH also in patients treated with CTLA4- and PD-1/PD-L1-directed checkpoint antibodies (ipilimumab, pembrolizumab, nivolumab, avelumab, atezolizumab), which are used in a variety of cancer subtypes. Treatment interruption or corticosteroids alone have been used with meaningful responses.^{119,120} A CART cell-associated toxicity working group suggests that suspected HLH should be managed with anti-IL-6 therapy and corticosteroids for organ toxicities \geq grade 3; if the patient has no improvement clinically or serologically within 48 hours, additional therapy with etoposide (75 to 100 mg/m²) should be considered.¹²¹

Summary and perspectives

In recent years, interest in adult HLH has increased markedly; as a result, HLH is more frequently diagnosed in adults. The dramatic therapeutic success in pediatric HLH has also positively affected the survival of adults with HLH. However, there are profound differences between adult and pediatric HLH; genetic HLH is rare in adults, pediatric diagnostic criteria are suboptimal, frequent (often occult) underlying malignancies or other conditions require a different diagnostic workup, and pediatric treatment regimens may have to be adapted on a case-by-case basis.

In adults, HLH-associated mortality remains high, especially in patients with underlying malignancies. Although the drugs used in pediatric HLH are effective in adult HLH, there is a need for novel agents. Interesting trials testing alternative therapeutic approaches have been initiated, including those incorporating ruxolitinib (JAK1/2 inhibitor; ClinicalTrials.gov identifiers NCT02400463, NCT03795909, NCT03533790), anakinra (IL-1 blockade; NCT02780583), alemtuzumab (NCT02472054), and emapalumab (anti-IFN- γ monoclonal antibody; NCT01818492). It is anticipated that the increased awareness of HLH, together with a more rapid diagnostic workup and new therapeutic approaches, will improve the prognosis of HLH in adults, as has been the case in children.

Acknowledgments

This work was supported by grants from Europe for Thuringia (Thüringer Aufbaubank; P.L.R.) and from the Swedish Children's Cancer Foundation, the Swedish Cancer Foundation, the Cancer and Allergy Foundation of Sweden, and the Stockholm County Council (ALF project) (J.-I.H.).

Authorship

Contribution: P.L.R. initiated the report, which was planned and coordinated by P.L.R. and J.-I.H.; A.H., M.H., T.v.B.G., R.M., N.B., S.B., J.G.-H., M.G., M.B.J., A.K., J.A.M.v.L., G.L., K.E.N., A.V.R., Y.W., Z.W., and G.J. contributed text proposals and revisions; all authors voted on all statements; and P.L.R. and J.-I.H. drafted the manuscript, which was reviewed and approved by all authors.

Conflict-of-interest disclosure: A.H. has received speakers' fees/honoraria from Sobi and Novartis. M.B.J. and A.K. have acted as consultants for Novimmune and Sobi. K.E.N. has received research support from Incyte Pharmaceuticals and Alpine Biosciences. A.V.R. has received speakers' fees/honoraria from SOBI, Novartis, Lilly, and Roche. The remaining authors declare no competing financial interests.

ORCID profiles: P.L.R., 0000-0002-6758-7809; T.v.B.G., 0000-0001-6322-8035; R.M., 0000-0002-2077-6610; N.B., 0000-0001-7502-6895;

M.G., 0000-0003-3270-411X; A.K., 0000-0002-8306-8419; G.L., 0000-0003-2330-9839; K.E.N., 0000-0002-5581-6555; A.V.R., 0000-0001-8663-2401.

Correspondence: Paul La Rosée, Klinik für Innere Medizin II, Hämatologie, Onkologie, Immunologie, Infektiologie und Palliativmedizin, Schwarzwald-Baar-Klinikum gGmbH, Klinikstr. 11, D-78052 Villingen-Schwenningen, Germany; e-mail: paul.larosee@sbk-vs.de; and Jan-Inge Henter, Childhood Cancer Research Unit, Karolinska Institutet, Tomtebodavägen 18A, SE-171 77 Stockholm, Sweden; e-mail: jan-inge.henter@ki.se.

Footnote

Submitted 31 December 2018; accepted 12 April 2019. Prepublished online as *Blood* First Edition paper, 16 April 2019; DOI 10.1182/blood.2018894618.

REFERENCES

- Machowicz R, Janka G, Wiktor-Jedrzejczak W. Your critical care patient may have HLH (hemophagocytic lymphohistiocytosis). *Crit Care*. 2016;20(1):215.
- Machowicz R, Janka G, Wiktor-Jedrzejczak W. Similar but not the same: differential diagnosis of HLH and sepsis. *Crit Rev Oncol Hematol*. 2017;114:1-12.
- Trottestam H, Horne A, Aricó M, et al; Histiocyte Society. Chemoimmunotherapy for hemophagocytic lymphohistiocytosis: long-term results of the HLH-94 treatment protocol. *Blood*. 2011;118(17):4577-4584.
- Henter JI, Horne A, Aricó M, et al. HLH-2004: diagnostic and therapeutic guidelines for hemophagocytic lymphohistiocytosis. *Pediatr Blood Cancer*. 2007;48(2):124-131.
- Bergsten E, Horne A, Aricó M, et al. Confirmed efficacy of etoposide and dexamethasone in HLH treatment: long-term results of the cooperative HLH-2004 study. *Blood*. 2017;130(25):2728-2738.
- Ehl S, Astigarraga I, von Bahr Greenwood T, et al. Recommendations for the use of etoposide-based therapy and bone marrow transplantation for the treatment of HLH: consensus statements by the HLH Steering Committee of the Histiocyte Society. *J Allergy Clin Immunol Pract*. 2018;6(5):1508-1517.
- Brisse E, Wouters CH, Matthys P. Hemophagocytic lymphohistiocytosis (HLH): a heterogeneous spectrum of cytokine-driven immune disorders. *Cytokine Growth Factor Rev*. 2015;26(3):263-280.
- Schulert GS, Canna SW. Convergent pathways of the hyperferritinemic syndromes. *Int Immunol*. 2018;30(5):195-203.
- La Rosée P. Treatment of hemophagocytic lymphohistiocytosis in adults. *Hematology Am Soc Hematol Educ Program*. 2015;2015:190-196.
- Ramos-Casals M, Brito-Zerón P, López-Guillermo A, Khamashta MA, Bosch X. Adult haemophagocytic syndrome. *Lancet*. 2014;383(9927):1503-1516.
- Janka GE, Lehmborg K. Hemophagocytic syndromes—an update. *Blood Rev*. 2014;28(4):135-142.
- Emile JF, Abela O, Frairot S, et al; Histiocyte Society. Revised classification of histiocytoses and neoplasms of the macrophage-dendritic cell lineages. *Blood*. 2016;127(22):2672-2681.
- Sepulveda FE, de Saint Basile G. Hemophagocytic syndrome: primary forms and predisposing conditions. *Curr Opin Immunol*. 2017;49:20-26.
- Rouphael NG, Talati NJ, Vaughan C, Cunningham K, Moreira R, Gould C. Infections associated with hemophagocytic syndrome. *Lancet Infect Dis*. 2007;7(12):814-822.
- Lehmborg K, Nichols KE, Henter JI, et al; Study Group on Hemophagocytic Lymphohistiocytosis Subtypes of the Histiocyte Society. Consensus recommendations for the diagnosis and management of hemophagocytic lymphohistiocytosis associated with malignancies. *Haematologica*. 2015;100(8):997-1004.
- Daver N, McClain K, Allen CE, et al. A consensus review on malignancy-associated hemophagocytic lymphohistiocytosis in adults. *Cancer*. 2017;123(17):3229-3240.
- Machaczka M, Vaktnäs J, Klimkowska M, Häggglund H. Malignancy-associated hemophagocytic lymphohistiocytosis in adults: a retrospective population-based analysis from a single center. *Leuk Lymphoma*. 2011;52(4):613-619.
- Ishii E, Ohga S, Imashuku S, et al. Nationwide survey of hemophagocytic lymphohistiocytosis in Japan. *Int J Hematol*. 2007;86(1):58-65.
- Hayden A, Park S, Giustini D, Lee AY, Chen LY. Hemophagocytic syndromes (HPS) including hemophagocytic lymphohistiocytosis (HLH) in adults: a systematic scoping review. *Blood Rev*. 2016;30(6):411-420.
- La Rosée P. First prospective clinical trial in adult HLH. *Blood*. 2015;126(19):2169-2171.
- Rivière S, Galicier L, Coppo P, et al. Reactive hemophagocytic syndrome in adults: a retrospective analysis of 162 patients. *Am J Med*. 2014;127(11):1118-1125.
- Delavigne K, Bérard E, Bertoli S, et al. Hemophagocytic syndrome in patients with acute myeloid leukemia undergoing intensive chemotherapy. *Haematologica*. 2014;99(3):474-480.
- Sano H, Kobayashi R, Tanaka J, et al. Risk factor analysis of non-Hodgkin lymphoma-associated hemophagocytic syndromes: a multicentre study. *Br J Haematol*. 2014;165(6):786-792.
- Henter JI, Elinder G, Ost A; The FHL Study Group of the Histiocyte Society. Diagnostic guidelines for hemophagocytic lymphohistiocytosis. *Semin Oncol*. 1991;18(1):29-33.
- Machowicz R, Kröger N, Krieger T, et al. Hyperferritinemia in adult HLH: the best what we have, so far [published e-Letter response 23 April 2015]. *Blood*. 2015;125(10):1548-1552.
- Schram AM, Campigotto F, Mullally A, et al. Marked hyperferritinemia does not predict for HLH in the adult population. *Blood*. 2015;125(10):1548-1552.
- Schram AM, Berliner N. How I treat hemophagocytic lymphohistiocytosis in the adult patient. *Blood*. 2015;125(19):2908-2914.
- Allen CE, Yu X, Kozinetz CA, McClain KL. Highly elevated ferritin levels and the diagnosis of hemophagocytic lymphohistiocytosis. *Pediatr Blood Cancer*. 2008;50(6):1227-1235.
- Lin M, Park S, Hayden A, et al. Clinical utility of soluble interleukin-2 receptor in hemophagocytic syndromes: a systematic scoping review. *Ann Hematol*. 2017;96(8):1241-1251.
- Hayden A, Lin M, Park S, et al. Soluble interleukin-2 receptor is a sensitive diagnostic test in adult HLH. *Blood Adv*. 2017;1(26):2529-2534.
- Schram AM, Comstock P, Campo M, et al. Hemophagocytic lymphohistiocytosis in adults: a multicentre case series over 7 years. *Br J Haematol*. 2016;172(3):412-419.
- de Kerguenec C, Hillaire S, Molinié V, et al. Hepatic manifestations of hemophagocytic syndrome: a study of 30 cases. *Am J Gastroenterol*. 2001;96(3):852-857.
- Arca M, Fardet L, Galicier L, et al. Prognostic factors of early death in a cohort of 162 adult hemophagocytic syndrome: impact of triggering disease and early treatment with etoposide. *Br J Haematol*. 2015;168(1):63-68.

34. Li F, Yang Y, Jin F, et al. Clinical characteristics and prognostic factors of adult hemophagocytic syndrome patients: a retrospective study of increasing awareness of a disease from a single-center in China. *Orphanet J Rare Dis*. 2015;10(1):20.
35. Parikh SA, Kapoor P, Letendre L, Kumar S, Wolanskyj AP. Prognostic factors and outcomes of adults with hemophagocytic lymphohistiocytosis. *Mayo Clin Proc*. 2014;89(4):484-492.
36. Park HS, Kim DY, Lee JH, et al. Clinical features of adult patients with secondary hemophagocytic lymphohistiocytosis from causes other than lymphoma: an analysis of treatment outcome and prognostic factors. *Ann Hematol*. 2012;91(6):897-904.
37. Otrrock ZK, Eby CS. Clinical characteristics, prognostic factors, and outcomes of adult patients with hemophagocytic lymphohistiocytosis. *Am J Hematol*. 2015;90(3):220-224.
38. Yu JT, Wang CY, Yang Y, et al. Lymphoma-associated hemophagocytic lymphohistiocytosis: experience in adults from a single institution. *Ann Hematol*. 2013;92(11):1529-1536.
39. Tamamyian GN, Kantarjian HM, Ning J, et al. Malignancy-associated hemophagocytic lymphohistiocytosis in adults: relation to hemophagocytosis, characteristics, and outcomes. *Cancer*. 2016;122(18):2857-2866.
40. Li J, Wang Q, Zheng W, et al. Hemophagocytic lymphohistiocytosis: clinical analysis of 103 adult patients. *Medicine (Baltimore)*. 2014;93(2):100-105.
41. Wang Y, Wang Z, Zhang J, et al. Genetic features of late onset primary hemophagocytic lymphohistiocytosis in adolescence or adulthood. *PLoS One*. 2014;9(9):e107386.
42. Fardet L, Galicier L, Lambotte O, et al. Development and validation of the HScore, a score for the diagnosis of reactive hemophagocytic syndrome. *Arthritis Rheumatol*. 2014;66(9):2613-2620.
43. Xu XJ, Tang YM, Song H, et al. Diagnostic accuracy of a specific cytokine pattern in hemophagocytic lymphohistiocytosis in children. *J Pediatr*. 2012;160(6):984-990.e1.
44. Han XC, Ye Q, Zhang WY, Tang YM, Xu XJ, Zhang T. Cytokine profiles as novel diagnostic markers of Epstein-Barr virus-associated hemophagocytic lymphohistiocytosis in children. *J Crit Care*. 2017;39:72-77.
45. Zondag TC, Roxk C, van Lom K, et al. Cytokine and viral load kinetics in human herpesvirus 8-associated multicentric Castelman's disease complicated by hemophagocytic lymphohistiocytosis. *Int J Hematol*. 2016;103(4):469-472.
46. Bode SF, Ammann S, Al-Herz W, et al; Inborn Errors Working Party of the EBMT. The syndrome of hemophagocytic lymphohistiocytosis in primary immunodeficiencies: implications for differential diagnosis and pathogenesis. *Haematologica*. 2015;100(7):978-988.
47. Pachlopnik Schmid J, Canioni D, Moshous D, et al. Clinical similarities and differences of patients with X-linked lymphoproliferative syndrome type 1 (XLP-1/SAP deficiency) versus type 2 (XLP-2/XIAP deficiency). *Blood*. 2011;117(5):1522-1529.
48. Bryceson YT, Pende D, Maul-Pavicic A, et al. A prospective evaluation of degranulation assays in the rapid diagnosis of familial hemophagocytic syndromes. *Blood*. 2012;119(12):2754-2763.
49. Kogawa K, Lee SM, Villanueva J, Mamer D, Sumeji J, Filipovich AH. Perforin expression in cytotoxic lymphocytes from patients with hemophagocytic lymphohistiocytosis and their family members. *Blood*. 2002;99(1):61-66.
50. Marsh RA, Bleesing JJ, Filipovich AH. Using flow cytometry to screen patients for X-linked lymphoproliferative disease due to SAP deficiency and XIAP deficiency. *J Immunol Methods*. 2010;362(1-2):1-9.
51. Cetica V, Sieni E, Pende D, et al. Genetic predisposition to hemophagocytic lymphohistiocytosis: report on 500 patients from the Italian registry. *J Allergy Clin Immunol*. 2016;137(1):188-196.e4.
52. Zhang K, Jordan MB, Marsh RA, et al. Hypomorphic mutations in PRF1, MUNC13-4, and STXBP2 are associated with adult-onset familial HLH. *Blood*. 2011;118(22):5794-5798.
53. Voskoboinik I, Trapani JA. Perforinopathy: a spectrum of human immune disease caused by defective perforin delivery or function. *Front Immunol*. 2013;4:441.
54. Bains A, Mamone L, Aneja A, Bromberg M. Lymphoid malignancy-associated hemophagocytic lymphohistiocytosis: search for the hidden source. *Ann Diagn Pathol*. 2017;28:37-42.
55. Ponzoni M, Campo E, Nakamura S. Intravascular large B-cell lymphoma: a chameleon with multiple faces and many masks. *Blood*. 2018;132(15):1561-1567.
56. Yuan L, Kan Y, Meeks JK, Ma D, Yang J. 18F-FDG PET/CT for identifying the potential causes and extent of secondary hemophagocytic lymphohistiocytosis. *Diagn Interv Radiol*. 2016;22(5):471-475.
57. Tabata C, Tabata R. Possible prediction of underlying lymphoma by high sIL-2R/ferritin ratio in hemophagocytic syndrome. *Ann Hematol*. 2012;91(1):63-71.
58. Jing-Shi W, Yi-Ni W, Lin W, Zhao W. Splenectomy as a treatment for adults with relapsed hemophagocytic lymphohistiocytosis of unknown cause. *Ann Hematol*. 2015;94(5):753-760.
59. Johnson TS, Terrell CE, Millen SH, Katz JD, Hildeman DA, Jordan MB. Etoposide selectively ablates activated T cells to control the immunoregulatory disorder hemophagocytic lymphohistiocytosis. *J Immunol*. 2014;192(1):84-91.
60. Imashuku S, Teramura T, Kuriyama K, et al. Risk of etoposide-related acute myeloid leukemia in the treatment of Epstein-Barr virus-associated hemophagocytic lymphohistiocytosis. *Int J Hematol*. 2002;75(2):174-177.
61. Janka GE, Lehmborg K. Hemophagocytic lymphohistiocytosis: pathogenesis and treatment. *Hematology Am Soc Hematol Educ Program*. 2013;2013:605-611.
62. Cooper N, Rao K, Gilmour K, et al. Stem cell transplantation with reduced-intensity conditioning for hemophagocytic lymphohistiocytosis. *Blood*. 2006;107(3):1233-1236.
63. Machowicz R, Suarez F, Jedrzejczak WW, et al. Allogeneic hematopoietic stem cell transplantation in hemophagocytic lymphohistiocytosis (HLH) in adults: a retrospective study of the Chronic Malignancies and Inborn Errors Working Parties (CMWP and IEWP) of the EBMT. *Blood*. 2016;128(22):3490.
64. Fu L, Wang J, Wei N, et al. Allogeneic hematopoietic stem-cell transplantation for adult and adolescent hemophagocytic lymphohistiocytosis: a single center analysis. *Int J Hematol*. 2016;104(5):628-635.
65. Berliner N, Kurra C, Chou D. Case Records of the Massachusetts General Hospital. Case 1-2016. An 18-year-old man with fever, abdominal pain, and thrombocytopenia. *N Engl J Med*. 2016;374(2):165-173.
66. Imashuku S, Kuriyama K, Sakai R, et al. Treatment of Epstein-Barr virus-associated hemophagocytic lymphohistiocytosis (EBV-HLH) in young adults: a report from the HLH study center. *Med Pediatr Oncol*. 2003;41(2):103-109.
67. Henter JI, Chow CB, Leung CW, Lau YL. Cytotoxic therapy for severe avian influenza A (H5N1) infection. *Lancet*. 2006;367(9513):870-873.
68. Larroche C, Bruneel F, André MH, et al; Comité d'Evaluation et de Diffusion des Innovations Technologiques (CEDIT). [Intravenously administered gamma-globulins in reactive hemophagocytic syndrome. Multicenter study to assess their importance, by the immunoglobulins group of experts of CEDIT of the AP-HP]. *Ann Med Interne (Paris)*. 2000;151(7):533-539.
69. Emmenegger U, Spaeth PJ, Neftel KA. Intravenous immunoglobulin for hemophagocytic lymphohistiocytosis? *J Clin Oncol*. 2002;20(2):599-601.
70. Néel A, Wahbi A, Tessoulin B, et al. Diagnostic and management of life-threatening adult-onset Still disease: a French nationwide multicenter study and systematic literature review. *Crit Care*. 2018;22(1):88.
71. Shakoory B, Carcillo JA, Chatham WW, et al. Interleukin-1 receptor blockade is associated with reduced mortality in sepsis patients with features of macrophage activation syndrome: reanalysis of a prior phase III trial. *Crit Care Med*. 2016;44(2):275-281.
72. Schmitz N, Zeynalova S, Nickelsen M, et al. CNS International Prognostic Index: a risk model for CNS relapse in patients with diffuse large B-cell lymphoma treated with R-CHOP. *J Clin Oncol*. 2016;34(26):3150-3156.
73. Wilhelm M, Smetak M, Reimer P, et al. First-line therapy of peripheral T-cell lymphoma: extension and long-term follow-up of a study investigating the role of autologous stem cell transplantation. *Blood Cancer J*. 2016;6(7):e452.

74. Tsuchiyama J, Imajo K, Yoshino T, et al. High-dose chemotherapy and autologous peripheral blood stem cell transplantation for treatment of unspecified peripheral T-cell lymphoma presented with hepatosplenomegaly and hypercytokinemia syndrome: report of three cases. *Ann Hematol*. 2002;81(10):588-592.
75. Machaczka M, Klimkowska M, Chiang SC, et al. Development of classical Hodgkin's lymphoma in an adult with biallelic STXP2 mutations. *Haematologica*. 2013;98(5):760-764.
76. Imashuku S, Hibi S, Ohara T, et al; Histiocyte Society. Effective control of Epstein-Barr virus-related hemophagocytic lymphohistiocytosis with immunochemotherapy. *Blood*. 1999;93(6):1869-1874.
77. van Laar JA, Buysse CM, Vossen AC, et al. Epstein-Barr viral load assessment in immunocompetent patients with fulminant infectious mononucleosis. *Arch Intern Med*. 2002;162(7):837-839.
78. Chellapandian D, Das R, Zellek K, et al; EBV-HLH Rituximab Study Group. Treatment of Epstein Barr virus-induced haemophagocytic lymphohistiocytosis with rituximab-containing chemo-immunotherapeutic regimens. *Br J Haematol*. 2013;162(3):376-382.
79. Beutel K, Gross-Wielsch U, Wiesel T, Stadt UZ, Janka G, Wagner HJ. Infection of T lymphocytes in Epstein-Barr virus-associated hemophagocytic lymphohistiocytosis in children of non-Asian origin. *Pediatr Blood Cancer*. 2009;53(2):184-190.
80. Sawada A, Inoue M, Kawa K. How we treat chronic active Epstein-Barr virus infection. *Int J Hematol*. 2017;105(4):406-418.
81. Fujiwara S, Kimura H, Imadome K, et al. Current research on chronic active Epstein-Barr virus infection in Japan. *Pediatr Int*. 2014;56(2):159-166.
82. Fardet L, Lambotte O, Meynard JL, et al. Reactive haemophagocytic syndrome in 58 HIV-1-infected patients: clinical features, underlying diseases and prognosis. *AIDS*. 2010;24(9):1299-1306.
83. Gagnaire MH, Galambrun C, Stéphan JL. Hemophagocytic syndrome: a misleading complication of visceral leishmaniasis in children--a series of 12 cases. *Pediatrics*. 2000;106(4):E58.
84. WHO Treatment Guidelines for Drug-Resistant Tuberculosis (2016 update). Geneva, Switzerland: World Health Organization; 2016.
85. Wang Y, Huang W, Hu L, et al. Multicenter study of combination DEP regimen as a salvage therapy for adult refractory hemophagocytic lymphohistiocytosis. *Blood*. 2015;126(19):2186-2192.
86. Imashuku S, Kudo N, Kubo K, Yachie A. Are regimens containing rituximab effective in the initial treatment of Epstein-Barr virus-positive natural killer cell lymphoproliferative disease-associated hemophagocytic lymphohistiocytosis? *Int J Hematol*. 2013;98(3):375-377.
87. Marsh RA, Allen CE, McClain KL, et al. Salvage therapy of refractory hemophagocytic lymphohistiocytosis with alemtuzumab. *Pediatr Blood Cancer*. 2013;60(1):101-109.
88. Strout MP, Seropian S, Berliner N. Alemtuzumab as a bridge to allogeneic SCT in atypical hemophagocytic lymphohistiocytosis. *Nat Rev Clin Oncol*. 2010;7(7):415-420.
89. La Rosée P. Alleviating the storm: ruxolitinib in HLH. *Blood*. 2016;127(13):1626-1627.
90. Sin JH, Zangardi ML. Ruxolitinib for secondary hemophagocytic lymphohistiocytosis: first case report [published online ahead of print 16 August 2017]. *Hematol Oncol Stem Cell Ther*. doi:10.1016/j.hemonc.2017.07.002.
91. Frimmel S, Schipper J, Henschel J, Yu TT, Mitzner SR, Kobal S. First description of single-pass albumin dialysis combined with cytokine adsorption in fulminant liver failure and hemophagocytic syndrome resulting from generalized herpes simplex virus 1 infection. *Liver Transpl*. 2014;20(12):1523-1524.
92. Greil C, Roether F, La Rosée P, Grimbacher B, Duerschmied D, Warnatz K. Rescue of Cytokine Storm Due to HLH by Hemoadsorption in a CTLA4-Deficient Patient. *J Clin Immunol*. 2017;37(3):273-276.
93. Locatelli F, Jordan MB, Allen CE, et al. Safety and efficacy of emapalumab in pediatric patients with primary hemophagocytic lymphohistiocytosis. *Blood*. 2018;132(suppl 1):LBA-6.
94. Buysse S, Teixeira L, Galicier L, et al. Critical care management of patients with hemophagocytic lymphohistiocytosis. *Intensive Care Med*. 2010;36(10):1695-1702.
95. Lachmann G, Spies C, Schenk T, Brunkhorst FM, Balzer F, La Rosée P. Hemophagocytic lymphohistiocytosis: potentially underdiagnosed in intensive care units. *Shock*. 2018;50(2):149-155.
96. Carcillo JA, Podd B, Simon DW. From febrile pancytopenia to hemophagocytic lymphohistiocytosis-associated organ dysfunction. *Intensive Care Med*. 2017;43(12):1853-1855.
97. Carcillo JA, Sward K, Halstead ES, et al; Eunice Kennedy Shriver National Institute of Child Health and Human Development Collaborative Pediatric Critical Care Research Network Investigators. A systemic inflammation mortality risk assessment contingency table for severe sepsis. *Pediatr Crit Care Med*. 2017;18(2):143-150.
98. Kyriazopoulou E, Leventogiannis K, Norrby-Teglund A, et al; Hellenic Sepsis Study Group. Macrophage activation-like syndrome: an immunological entity associated with rapid progression to death in sepsis. *BMC Med*. 2017;15(1):172.
99. Castillo L, Carcillo J. Secondary hemophagocytic lymphohistiocytosis and severe sepsis/ systemic inflammatory response syndrome/multiorgan dysfunction syndrome/macrophage activation syndrome share common intermediate phenotypes on a spectrum of inflammation. *Pediatr Crit Care Med*. 2009;10(3):387-392.
100. Rajagopala S, Singh N, Agarwal R, Gupta D, Das R. Severe hemophagocytic lymphohistiocytosis in adults-experience from an intensive care unit from North India. *Indian J Crit Care Med*. 2012;16(4):198-203.
101. Créput C, Galicier L, Buysse S, Azoulay E. Understanding organ dysfunction in hemophagocytic lymphohistiocytosis. *Intensive Care Med*. 2008;34(7):1177-1187.
102. Kumar B, Aleem S, Saleh H, Petts J, Ballas ZK. A personalized diagnostic and treatment approach for macrophage activation syndrome and secondary hemophagocytic lymphohistiocytosis in adults. *J Clin Immunol*. 2017;37(7):638-643.
103. Wohlfarth P, Agis H, Gualdoni GA, et al. Interleukin 1 receptor antagonist anakinra, intravenous immunoglobulin, and corticosteroids in the management of critically ill adult patients with hemophagocytic lymphohistiocytosis [published online ahead of print 16 August 2017]. *J Intensive Care Med*. doi:10.1177/0885066617711386.
104. Gavand PE, Serio I, Arnaud L, et al. Clinical spectrum and therapeutic management of systemic lupus erythematosus-associated macrophage activation syndrome: a study of 103 episodes in 89 adult patients. *Autoimmun Rev*. 2017;16(7):743-749.
105. Asanuma YF, Mimura T, Tsuboi H, et al. Nationwide epidemiological survey of 169 patients with adult Still's disease in Japan. *Mod Rheumatol*. 2015;25(3):393-400.
106. Batu ED, Erden A, Seyhoğlu E, et al. Assessment of the HScore for reactive hemophagocytic syndrome in patients with rheumatic diseases. *Scand J Rheumatol*. 2017;46(1):44-48.
107. Ravelli A, Minoia F, Davi S, et al; Histiocyte Society. 2016 classification criteria for macrophage activation syndrome complicating systemic juvenile idiopathic arthritis: a European League Against Rheumatism/American College of Rheumatology/Paediatric Rheumatology International Trials Organisation collaborative initiative. *Ann Rheum Dis*. 2016;75(3):481-489.
108. Ravelli A, Minoia F, Davi S, et al. Expert consensus on dynamics of laboratory tests for diagnosis of macrophage activation syndrome complicating systemic juvenile idiopathic arthritis. *RMD Open*. 2016;2(1):e000161.
109. Minoia F, Bovis F, Davi S, et al. Development and initial validation of the Macrophage Activation Syndrome/Primary Hemophagocytic Lymphohistiocytosis Score, a diagnostic tool that differentiates primary hemophagocytic lymphohistiocytosis from macrophage activation syndrome. *J Pediatr*. 2017;189:72-78.e3.
110. Schuler GS, Minoia F, Bohnsack J, et al. Effect of biologic therapy on clinical and laboratory features of macrophage activation syndrome associated with systemic juvenile idiopathic arthritis. *Arthritis Care Res (Hoboken)*. 2018;70(3):409-419.
111. Carter SJ, Tattersall RS, Ramanan AV. Macrophage activation syndrome in adults: recent advances in pathophysiology,

- diagnosis and treatment. *Rheumatology (Oxford)*. 2019;58(1):5-17.
112. Stoll ML, Cron RQ. Treatment of juvenile idiopathic arthritis: a revolution in care. *Pediatr Rheumatol Online J*. 2014;12(1):13.
113. Gerfaud-Valentin M, Jamilloux Y, Iwaz J, Sève P. Adult-onset Still's disease. *Autoimmun Rev*. 2014;13(7):708-722.
114. Zhou S, Qiao J, Bai J, Wu Y, Fang H. Biological therapy of traditional therapy-resistant adult-onset Still's disease: an evidence-based review. *Ther Clin Risk Manag*. 2018;14:167-171.
115. Teachey DT, Lacey SF, Shaw PA, et al. Identification of predictive biomarkers for cytokine release syndrome after chimeric antigen receptor T-cell therapy for acute lymphoblastic leukemia. *Cancer Discov*. 2016;6(6):664-679.
116. Teachey DT, Rheingold SR, Maude SL, et al. Cytokine release syndrome after blinatumomab treatment related to abnormal macrophage activation and ameliorated with cytokine-directed therapy. *Blood*. 2013; 121(26):5154-5157.
117. Neelapu SS, Locke FL, Bartlett NL, et al. Axicabtagene ciloleucel CAR T-cell therapy in refractory large B-cell lymphoma. *N Engl J Med*. 2017;377(26):2531-2544.
118. Kantarjian H, Stein A, Gökbuğet N, et al. Blinatumomab versus chemotherapy for advanced acute lymphoblastic leukemia. *N Engl J Med*. 2017;376(9): 836-847.
119. Sadaat M, Jang S. Hemophagocytic lymphohistiocytosis with immunotherapy: brief review and case report. *J Immunother Cancer*. 2018;6(1):49.
120. Hantel A, Gabster B, Cheng JX, Golomb H, Gajewski TF. Severe hemophagocytic lymphohistiocytosis in a melanoma patient treated with ipilimumab + nivolumab. *J Immunother Cancer*. 2018;6(1):73.
121. Neelapu SS, Tummala S, Kebriaei P, et al. Chimeric antigen receptor T-cell therapy - assessment and management of toxicities. *Nat Rev Clin Oncol*. 2018;15(1):47-62.
122. Romberg N, Al Moussawi K, Nelson-Williams C, et al. Mutation of NLRC4 causes a syndrome of enterocolitis and auto-inflammation. *Nat Genet*. 2014;46(10): 1135-1139.
123. Canna SW, Girard C, Malle L, et al. Life-threatening NLRC4-associated hyperinflammation successfully treated with IL-18 inhibition. *J Allergy Clin Immunol*. 2017; 139(5):1698-1701.
124. Chinn IK, Eckstein OS, Peckham-Gregory EC, et al. Genetic and mechanistic diversity in pediatric hemophagocytic lymphohistiocytosis. *Blood*. 2018;132(1): 89-100.
125. Sieni E, Cetica V, Piccin A, et al. Familial hemophagocytic lymphohistiocytosis may present during adulthood: clinical and genetic features of a small series. *PLoS One*. 2012;7(9):e44649.
126. Chen X, Wang F, Zhang Y, et al. Genetic variant spectrum in 265 Chinese patients with hemophagocytic lymphohistiocytosis: molecular analyses of PRF1, UNC13D, STX11, STXBP2, SH2D1A, and XIAP. *Clin Genet*. 2018;94(2): 200-212.



blood[®]

2019 133: 2465-2477

doi:10.1182/blood.2018894618 originally published online
April 16, 2019

Recommendations for the management of hemophagocytic lymphohistiocytosis in adults

Paul La Rosée, AnnaCarin Horne, Melissa Hines, Tatiana von Bahr Greenwood, Rafal Machowicz, Nancy Berliner, Sebastian Birndt, Juana Gil-Herrera, Michael Girschikofsky, Michael B. Jordan, Ashish Kumar, Jan A. M. van Laar, Gunnar Lachmann, Kim E. Nichols, Athimalaipet V. Ramanan, Yini Wang, Zhao Wang, Gritta Janka and Jan-Inge Henter

Updated information and services can be found at:

<http://www.bloodjournal.org/content/133/23/2465.full.html>

Articles on similar topics can be found in the following Blood collections

[Clinical Trials and Observations](#) (4974 articles)

[Free Research Articles](#) (5431 articles)

[Immunobiology and Immunotherapy](#) (5692 articles)

[Special Reports](#) (13 articles)

Information about reproducing this article in parts or in its entirety may be found online at:

http://www.bloodjournal.org/site/misc/rights.xhtml#repub_requests

Information about ordering reprints may be found online at:

<http://www.bloodjournal.org/site/misc/rights.xhtml#reprints>

Information about subscriptions and ASH membership may be found online at:

<http://www.bloodjournal.org/site/subscriptions/index.xhtml>